



Outbreak, Surveillance and Investigation Reports

Field Epidemiology Training Program, Bureau of Epidemiology
Department of Disease Control, Ministry of Public Health, Thailand

Tel: +6625901734-5, Fax: +6625918581, Email: osireditor@osirjournal.net, <http://www.osirjournal.net>

Investigation of A Severe Enteroviral Encephalitis and Circulating Genotypes during Hand, Foot and Mouth Disease Surge in Nakhon Ratchasima Province, Thailand, August 2011

Sukhum Piriapornpipat^{1,*}, Pittayawonganon C¹, Mungaomklang A³, Prasertsopon J⁴, Praekunatham H¹, Arjkumpa O¹, Wechwithan S¹, Chanumklang P², Noisumdaeng P⁴, Guntapong R⁵, Iamsirithaworn S¹, Puthavathana P⁴

1 Field Epidemiology Training Program, Bureau of Epidemiology, Department of Disease Control, Ministry of Public Health, Thailand

2 Provincial Health Office, Nakhon Ratchasima Province, Thailand

3 Nakhon Ratchasima Hospital, Thailand

4 Department of Microbiology, Faculty of Medicine, Siriraj Hospital, Mahidol University, Thailand

5 Enterovirus Section, National Institute of Health, Department of Medical Sciences, Ministry of Public Health, Thailand

*Corresponding author, email address: dr.sukhum@hotmail.com

Abstract

On 7 Aug 2011, a 1-month-old baby with encephalitis caused by unspecified enterovirus was reported during the period of widespread hand, foot and mouth disease (HFMD) outbreaks in Nakhon Ratchasima Province. An investigation was carried out to confirm the diagnosis, identify etiology of all severe enteroviral infection cases, determine magnitude of HFMD and enterovirus infection, including asymptomatic infections, and recommend prevention and control measures. A descriptive study was conducted by interviewing family members of the index case. Throat swab and stool specimens were collected to identify enterovirus. Survey on asymptomatic infection was done in schools attended by the index case's siblings. Stool culture and isolation for enterovirus were also performed. Coxsackie B5 virus was isolated from fresh stool specimens of the index case. Among total 244 students screened for HFMD symptoms in four schools, only seven (3%) met the suspect case definition. During HFMD outbreaks caused by EV-71 B5, coxsackie A16 and coxsackie B5, proportion of asymptomatic infection among students was 22%. Risk factors such as no soap in toilets and misuse of alcohol gel to clean hands in schools were observed during the environmental survey.

Keywords: encephalitis, HFMD, enterovirus, EV-71, coxsackie B5, Nakhon Ratchasima, Thailand

Introduction

Hand, foot and mouth disease (HFMD) is a common viral illness that mainly affects children under five years old. However, sometimes it can also affect adults. The disease is transmitted through direct contact with respiratory droplets, feces, blister fluid from palms, soles and oral mucosa, or contaminated objects and surfaces such as utensils in school.^{1,2} The disease is caused by a number of different genotypes of enterovirus, including enterovirus 71 (EV-71) and coxsackie A16. Spectrum of the disease ranges from asymptomatic or minor febrile illness and gastroenteritis to more severe syndromes, including aseptic meningitis, carditis and even fatal encephalomyocarditis in newborns.³⁻⁶ In addition, case

fatality ratio is high for HFMD with fulminant neurogenic pulmonary edema, especially in age group less than six months which is as high as 21%.⁷⁻⁹ HFMD and herpangina are frequently caused by several distinct serotypes belonging to human enterovirus A species. Therefore, surveillance should be set up to determine clinical and epidemiological characteristics of HFMD and herpangina associated with enterovirus infections.¹⁰

Many countries in Asia, especially China, have encountered various HFMD clusters among children with high number of fatal cases.¹¹ During 2006, Thailand had detected many HFMD cases and four deaths caused by enterovirus in a northeastern province, Nakhon Ratchasima.¹² Between May and

August 2011, the province had experienced HFMD outbreaks again, especially among school children. On 7 Aug 2011, the provincial health office notified the Bureau of Epidemiology that a 1-month-old male was admitted to a hospital with seizure, suspecting encephalitis caused by enteroviral infection. His cerebrospinal fluid (CSF) showed positive for unspecified enterovirus by polymerase chain reaction (PCR). Local and central surveillance and rapid response teams (SRRT) conducted an outbreak investigation on 8-31 Aug 2011 to confirm the diagnosis, identify etiology of all severe enteroviral infection cases, determine magnitude of HFMD and enterovirus infection, including asymptomatic infections, and recommend prevention and control measures.

Methods

HFMD Situation

We reviewed national epidemiological surveillance information (506 report form) on HFMD reported from Nakhon Ratchasima Province during 2006 to 2011.

We also reviewed medical records of the index case, interviewed family members and collected stool and throat swab specimens. In addition, we searched for severe HFMD cases and encephalitis cases aged under five years and admitted to the provincial hospital between January and August 2011.

We conducted an active case finding among patients diagnosed with HFMD or herpangina, and visited hospitals in Wang Nam Khiao (X) and Pak Thong Chai (Y) Districts in the province during 1-31 Aug 2011. We interviewed patients and household members about demographic data, clinical manifestations, onset dates and risk factors using semi-structured questionnaire. Moreover, stool samples were collected and tested for viral culture and isolation.

A suspect case was a villager from District X or Y who had oral ulcer with or without skin rash on palms and soles during 1-31 Aug 2011. A confirmed case was a suspect case tested positive for enterovirus by isolation with or without seroconversion by microneutralization test in acute and convalescent phase of serology.

An enteroviral encephalitis case was a person, who lived in X and Y Districts, developed fever and alteration of consciousness or seizure during 1 May to 31 Aug 2011 and had been confirmed by positive enteroviral isolation and/or seroconversion by microneutralization test.

Severe HFMD case was a HFMD case with severe complication involving heart or nervous system.

Persons with asymptomatic infection included household members or school contacts without symptoms, but were tested positive for enterovirus by isolation with or without seroconversion by microneutralization test in acute and convalescent phases of serology.

School Survey for Asymptomatic Infection

A survey on enteroviral infection was conducted among students in four schools attended by the index case's siblings. School A was located in District X while Schools B, C and D were in District Y. All schools provided education for kindergarten and primary school (age ranged 3-15 years). All students were screened for HFMD clinical manifestations by the investigation team and teachers. Students screened positive were interviewed by the team using structured questionnaire. Their stool samples and throat swabs were collected for viral culture and isolation. Throat swabs were collected from the suspect cases who had oral ulcer during last two weeks whereas fresh stool samples were collected from all family members and school children.

Laboratory Testing

Fresh stool samples and throat swabs were placed in dry containers, stored in refrigerators at 4-8°C and sent to Department of Microbiology, Faculty of Medicine, Siriraj Hospital, Mahidol University, Thailand for testing EV-71, coxsackie virus and *Enterovirus spp.* by viral culture, isolation and PCR.

In addition, 3-5 ml of serum was collected from severe HFMD and enteroviral encephalitis cases, and tested for serological titer of EV-71, coxsackie virus and *Enterovirus spp.* by microneutralization assay (Micro-NT) at the National Institution of Health (NIH), Department of Medical Science, Ministry of Public Health, Thailand.

Environmental Survey

Kitchen and toilet in the index case's house were inspected for sanitation. Other exposures were also assessed, including indirect contact transmission from public places such as public park or market.

In schools, we observed regular activities and inspected personal sanitation practices and environment that could be risk of transmission such as sharing of utensils, frequency of classroom cleaning, types of detergent, cleansing substances and soap in restrooms.

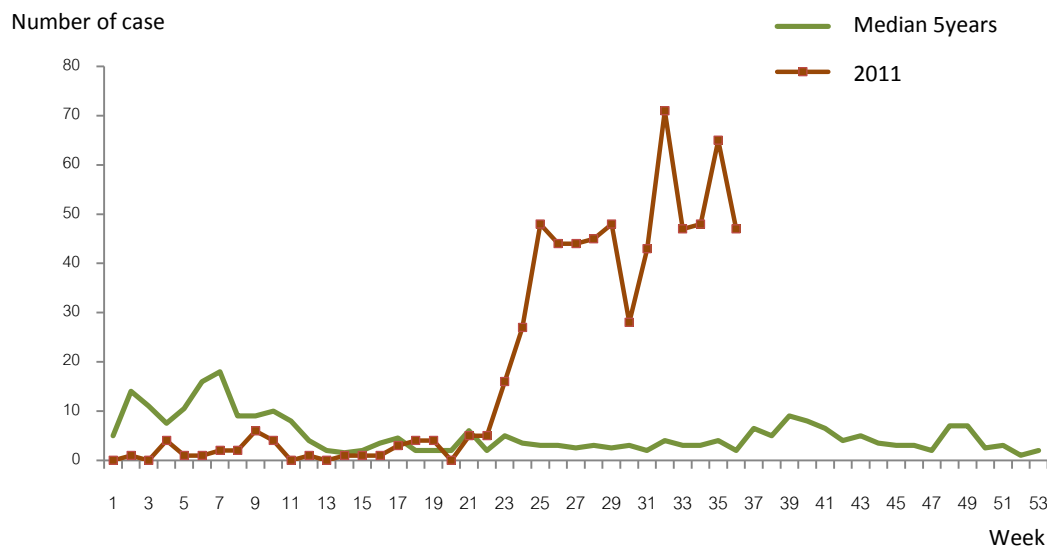


Figure 1. Number of reported HFMD cases by week and 5-year median in Nakhon Ratchasima Province, Thailand, 2011

Results

HFMD Situation

Number of HFMD cases reported to the Bureau of Epidemiology had increased since 20th week (May) of 2011 which was more than the median of the past five years (Figure 1). The period was correlated with semester opening of primary schools in Thailand.

Clinical Presentation and Exposures of the Index Case

On 31 Jul 2011, the index case, a 1-month-old Thai male, was brought to Wang Nam Khiao Hospital (Hospital X) with fever of 38°C and vomiting. At first, he was diagnosed with status epilepticus and acute viral infection. Few hours later, he developed generalized seizure and was transferred to the provincial hospital. After he was diagnosed of acute encephalitis, physician started antibiotics and provided ventilator support. He was treated with intravenous immunoglobulin (IVIG) the next day.

His CSF obtained on first day of admission was tested positive for *Enterovirus spp.* by viral culture and isolation at NIH. However, its genotype was not identified by PCR. Although the first stool sample collected four days after the onset was negative for enterovirus and coxsackie virus, the second stool sample collected one week later was positive for coxsackie B5 by stool viral isolation.

The index case lived with parents, elder twin brother and sister, and grandparents in District X. His mother was a teacher in School A and his father was a teacher in School D of District Y. His siblings were students in School B and C. Beside the index case, no other family members had symptoms of viral infection

one week before his onset. Their stool culture and isolation for enterovirus and coxsackie virus were negative.

Active Case Finding in Hospitals

From January to July 2011, there was no report of severe encephalitis caused by enterovirus in the provincial hospital. In August 2011, three new cases of severe enteroviral infection without vesicles on hands, foot and mouth were notified in the province. They were reported as suspected cases of enteroviral encephalitis by nurses in pediatric intensive care unit during the investigation period. Two of them died suddenly after diagnosed as EV-71 encephalitis. All of them lived in the same district as the index case. Local and central SRRT joined together and conducted the investigation to contain the outbreak.

Among 43 HFMD cases diagnosed in August 2011, 20 confirmed cases and eight suspected cases were from Hospital X, and two confirmed cases and 13 suspected cases were from the hospital in District Y (Hospital Y). Nineteen cases (44%) were males, with median age two years old (range one month to six years old). All of them were out-patients with no clinical presentation of severe enteroviral infection.

Among total 22 confirmed cases, 55% were tested positive for EV-71 (B5) from stool culture and viral isolation, 27% for coxsackie A16, 9% for coxsackie B5 and 9% for unidentified type of *Enterovirus spp.*

Asymptomatic Infection in School Survey

Family members of the index case had contact with total 244 students from Schools A, B, C and D. All students were screened for HFMD symptoms. Of seven suspected HFMD cases identified (2.9%), four

were from School B, with an overall attack rate of 5.9% (4/68), and three were from School C, with an attack rate of 3.8% (3/79). None of seven suspected cases were tested positive for enterovirus or coxsackie virus. Two (28.6%) out of seven cases were males and median age was 5.2, ranged 2-12.3 years old.

Students with asymptomatic infection were identified in all four schools, with EV-71 in School B and coxsackie B5 in Schools C and D. Average proportion of asymptomatic infection among students in these schools was 21.7% (53/244) (Table 1).

Circulating Genotypes of Enterovirus

A total of 287 fresh stool samples and 75 throat swabs were collected for viral isolation and PCR. Out of 287 samples, 82 were tested positive for enterovirus by PCR. EV-71 B5, coxsackie A16 and coxsackie B5 were identified in both districts, with 40.3% in District X and 25.3% in District Y. The circulating genotypes of enterovirus in hospitals, schools and communities were *Enterovirus spp.* (41/82, 50.0%), EV-71 B5

(25/82, 30.5%), coxsackie A16 (10/82, 12.2%) and coxsackie B5 (6/82, 7.3%).

All 50 cases with HFMD manifestations (28 suspected and 22 confirmed) from hospitals, communities and schools had oral ulcer (90%), rash on palm (79%), rash on sole (77%) and fever (67%) while other symptoms (<10%) were chest discomfort, seizure, gastrointestinal symptoms and rash on buttock. We found around 10% of clinical HFMD cases had only oral ulcer. Number of cases by onset date among patients in both hospitals and students of four schools was showed in figure 2.

Environmental Survey in Schools

School activities included learning in classrooms and playing or resting in the afternoon. Although they had lunch without sharing utensils, some shared milk bottles. Few soaps were provided for hand washing in toilets and children did not wash their hands properly. As teachers believed that enterovirus could be decontaminated by alcohol gel, all classrooms were

Table 1. Asymptomatic enterovirus infection in schools of Districts X and Y, Nakhon Ratchasima Province, Thailand, August 2011 (n=244)

School	Number of student			Enterovirus type			
	Total (n=244)	Symptomatic/suspected (%)	Asymptomatic infection (%)	EV-71 B5	Coxsackie B5	Coxsackie A16	Unidentified genotype
A	34	0	5 (15)	0	0	0	5
B	68	4 (6)	12 (18)	11	0	0	5
C	79	3 (4)	21 (27)	2	1	4	17
D	63	0	15 (24)	0	3	0	12

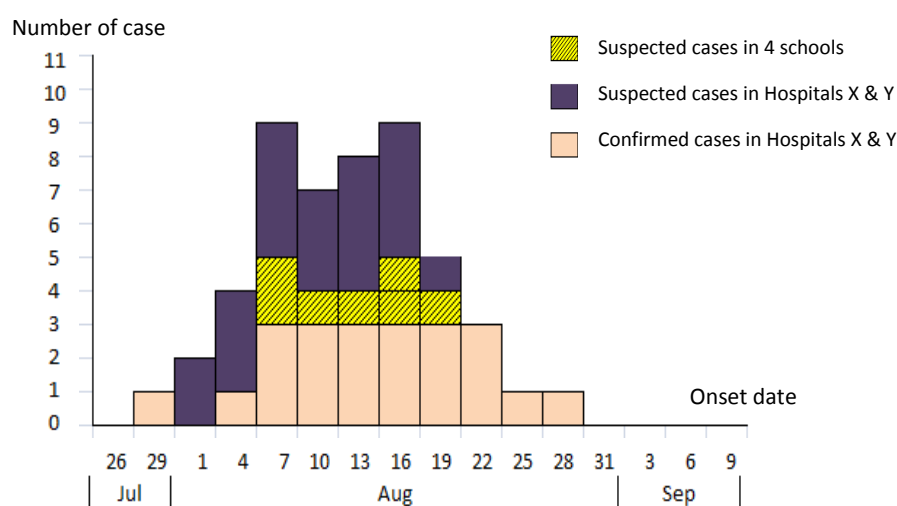


Figure 2. Suspected and confirmed HFMD cases in Districts X and Y, Nakhon Ratchasima Province, Thailand, August 2011 (n=50)



Figure 3. Environmental survey in 4 schools of Districts X and Y, Nakhon Ratchasima Province, Thailand, 2011

provided with alcohol gel instead of soap (Figure 3).

Follow up and Public Health Actions

After 35 days of hospitalization, the index case's clinical condition improved and was discharged from the hospital. One week later, he was in healthy condition with good neurological function.

Public education on mode of transmission of HFMD, case isolation and cleaning practice was provided to schools and affected communities. In addition, soaps were provided to schools and public toilets, and classroom cleaning was also promoted.

Discussion

In Thailand, number of severe HFMD deaths increased from zero in 2010 to six in following year.¹³ However, reason for the surge was not clear. Severe and fatal cases of HFMD and encephalitis were probably associated with emerging EV-71 genotype B5 and coxsackie B5 due to numerous outbreaks in communities and schools.¹⁴

Increasing dynamics circulation of multiple enteroviruses among reported HFMD cases in Nakhon Ratchasima Province during 2011 might be associated with concurrent outbreaks of EV-71 B5, coxsackie A16 and coxsackie B5. Interestingly, the index case of the outbreak was an infant who developed severe encephalitis without HFMD lesions in early August 2011. He had coxsackie B5 viral infection detected by PCR. Coxsackie B5 and EV-71 infections are also frequently associated with irregular cases of neurological diseases and epidemics of encephalitis.^{15,16}

There was no evidence of enterovirus circulating in the index case's family as stool culture and isolation of the family members for enterovirus and coxsackie virus revealed negative. Thus, with asymptomatic coxsackie B5 infection identified in Schools C and D, these schools were likely to be sources of the outbreak. From these sources, aerosol droplets might be route of transmission in this case and in the community outbreak which was similar to a previous study.¹⁷

Stool specimen isolated for *Enterovirus spp.* in human is highly specific for diagnosis of viral infection.¹⁸ In this study, stool specimen testing of students showed high proportion of asymptomatic enterovirus infection from stool culture (17.6%, 26.6%). Asymptomatic persons can also shed virus and transmit the disease in lower rate than symptomatic individuals, thereby creating an invisible 'reservoir' for the virus.¹⁹

Implication is that containment measures alone may not stop outbreak progression since asymptomatic cases still could be shedding the viruses and creating reservoirs. A better understanding on transmission dynamics is essential in planning to control enterovirus outbreaks.

Although impact on course of epidemic by school-closing strategy was not clear, children and schools are believed to play an important role in spread of the disease. Therefore, closing schools might slow down the propagation of an epidemic. After this investigation, the Ministry of Public Health advised schools with HFMD outbreak to close for one week when two or more cases were detected in the same classroom.

Limitations

Some healthy family members of HFMD cases did not participate in the study or provide stool samples, which might result in overestimation of infection rate if non-participating individuals were healthy. As active case finding of HFMD could not be conducted for the entire two districts, true magnitude of symptomatic HFMD cases was likely to be underestimated, especially the mild cases.

Conclusion

This is an outbreak of HFMD due to EV-71, coxsackie A16 and coxsackie B5 in schools and communities. The index case was confirmed to have encephalitis by coxsackie B5 virus. Asymptomatic infection was found in all four schools associated with the family members of the index case.

Public Health Actions and Recommendations

Small children were at high risk of transmission since they did not understand about personal hygiene. Therefore, teachers should work hard to enhance personal hygiene for children and teachers, including limited sharing of materials and utensils, and hand washing with soap after using toilet, before eating, before preparing food and after changing diapers.

Schools were recommended to close for one week if two or more HFMD cases were found in the same classroom in order to reduce transmission. In addition, when the school reopened, screening of students for oral ulcer and rash on palms and soles, and isolating of suspected students at home should be emphasized.

A proportion of suspected and confirmed cases had only oral ulcer. These cases were not reported in current notifiable disease surveillance system of Thailand which only reported cases that fulfilled the definition of HFMD. Therefore, herpangina was subsequently added into the list of reported diseases in notifiable disease surveillance system of Thailand.

Health care workers should be aware of linkage between encephalitis and HFMD, and explore etiology and source of infection. Protocol for cases management of severe HFMD must be available in hospitals. Children with HFMD should be attended by a pediatrician and considered for IVIG treatment to reduce severity.^{20,21}

Acknowledgements

We thank all local staff in Nakhon Ratchasima Provincial Health Office, Maharaj Nakhon Ratchasima Regional Hospital, Wang Nam Khiao Hospital and Pak Thong Chai Community Hospital for their valuable support in various activities that led to accomplish the study.

Suggested Citation

Piriyaornpipat S, Pittayawonganon C, Mungaomklang A, Prasertsopon J, Praekunatham H, Arjkumpa O, et al. Investigation of a severe enteroviral encephalitis and circulating genotypes during hand, foot and mouth disease surge in Nakhon Ratchasima Province, Thailand, August 2011. *OSIR*. 2014 Mar; 7(1):16-22.
<<http://osirjournal.net/issue.php?id=53>>.

References

- Centers for Disease Control and Prevention. Hand, foot, and mouth disease (HFMD). 2012 Apr 27. [cited 2013 Feb 8].
<<http://www.cdc.gov/hand-foot-mouth/about/index.html>>.
- Rajtar B, Majek M, Polański Ł, Polz-Dacewicz M. Enteroviruses in water environment--a potential threat to public health. *Ann Agric Environ Med*. 2008 Dec;15(2):199-203.
- Ashkenazi A, Melnick JL. Enteroviruses - a review of their properties and associated diseases. *Am J Clin Pathol*. 1962 Sep;38:209-29.
- Dery P, Marks MI, Shapera R. Clinical manifestations of Coxsackievirus infections in children. *Am J Dis Child*. 1974;128(4): 464-8.
- Sainani GS, Dekate MP, Rao CP. Heart disease caused by coxsackie virus B infection. *Br Heart J*. 1975 August; 37(8): 819-23.
- Whitehead JEM. Silent infections and the epidemiology of viral carditis. *Am Heart J*. 1973 May;85(5):711-3.
- Burch GE, Sun SC, Chu KC, Sohal RS, Colcolough HL. Interstitial and coxsackievirus B myocarditis in infants and children. A comparative histologic and immunofluorescent study of 50 autopsied hearts. *JAMA*. 1968 Jan 1;203(1):1-8.
- Gelfand HM, Holguin AH. Enterovirus infections in healthy children. *Arch Environ Health*. 1962;5(5):404-11.
- Chang LY, Huang YC, Lin TY. Fulminant neurogenic pulmonary oedema with hand, foot, and mouth disease. *Lancet*. 1998 Aug 1;352(9125):367-8.
- Mirand A, Henquell C, Archimbaud C, Ughetto S, Antona D, Bailly JL, et al. Outbreak of hand, foot and mouth disease/herpangina associated with coxsackievirus A6 and A10 infections in 2010, France: a large citywide, prospective observational study. *Clin Microbiol Infect*. 2012 May;18(5):E110-8. Epub 2012 Mar 8.
- Mizzima News. HFMD affecting children in Southeast Asia. 2012 Jul 26. [cited 2013 Feb 5]
<<http://www.mizzima.com/news/regional/7608-cattle-disease-affecting-children-in-southeast-asia.html>>.
- Buathong R, Hanshoaworakul W, Sutdan D, Iamsirithaworn S, Pongsuwanna Y, Puthawathana P, et al. Cluster of fatal cardiopulmonary failure among children caused by an emerging strain of enterovirus

- 71, Nakhorn Ratchasima Province, Thailand, 2006. *OSIR*. 2008 Aug;1(1):1-3.
13. Thailand. Bureau of Epidemiology. Department of Disease Control. Ministry of Public Health. Hand, foot and mouth disease surveillance. [cited 2013 May 1]. <http://www.boe.moph.go.th/boedb/d506_1/ds.php>.
14. Linsuwanon P, Puenpa J, Huang SW, Wang YF, Mauleekoonphairoj J, Wang JR, et al. Epidemiology and seroepidemiology of human enterovirus 71 among Thai populations, *J Biomed Sci*. 2014 Feb 18;21:16. doi: 10.1186/1423-0127-21-16.
15. Ma H, Huang X, Kang K, Li X, Tang X, Ren Y, et al. Recombination in human coxsackievirus B5 strains that caused an outbreak of viral encephalitis in Henan, China. *Arch Virol*. 2013 Oct;158(10):2169-73. Epub 2013 Apr 28.
16. Pérez-Vélez CM, Anderson MS, Robinson CC, McFarland EJ, Nix WA, Pallansch MA, et al. Outbreak of neurologic enterovirus type 71 disease: a diagnostic challenge. *Clin Infect Dis*. 2007 Oct 15;45(8):950-7. Epub 2007 Sep 13.
17. Wong SS, Yip CC, Lau SK, Yuen KY. Human enterovirus 71 and hand, foot and mouth disease. *Epidemiol Infect*. 2010 Aug;138(8):1071-89. Epub 2010 Jan 8.
18. Kupila L, Vuorinen T, Vainionpää R, Marttila RJ, Kotilainen P. Diagnosis of enteroviral meningitis by use of polymerase chain reaction of cerebrospinal fluid, stool, and serum specimens. *Clin Infect Dis*. 2005 Apr 1;40(7):982-7. Epub 2005 Mar 4.
19. Liu MY, Liu W, Luo J, Liu Y, Zhu Y, Berman H, et al. Characterization of an outbreak of hand, foot, and mouth disease in Nanchang, China in 2010. *PLoS ONE*. 2011 Sep;6(9):e25287.
20. Cao R, Han J, Qin E, Qin C. Mechanism of intravenous immunoglobulin therapy for severe hand-foot-mouth disease: a review. *Chinese journal of microbiology*. 2011 May;27(5):712-6.
21. He YX, Fu D, Cao DZ, Liu HY, Huang QL, Li CR. Critical care and therapy based different illness state of 80 patients with severe hand-foot-and-mouth disease seen in Shenzhen. *Chinese journal pediatric*. 2009 May;47(5):338-43.